



PATIENT

Layla Mendleson

SPECIES

Canine

BREED

Pomeranian

SEX

Female Spayed

AGE

10years

WEIGHT

12.4

INTERPRETED BY

Maggie Machen Lamy,
DVM, DACVIM
(Cardiology)

IMAGING PERFORMED BY

Sands Hill Mobile
Veterinary Ultrasound

HOSPITAL NAME

Whole Pet Vet

REFERRING VET

Dr. Calo

INVOICE

28598

DATE

1/27/23/23

PRESENTING CLINICAL SIGNS

History: Coughing, suspect tracheal collapse. Assess prior to dental.

RADIOGRAPHIC FINDINGS *NOTE: Images submitted for supplemental cardiac information only.
Cardiomegaly. No obvious evidence of CHF.

ECHOCARDIOGRAM FINDINGS

2D, m-mode, color flow and doppler imaging is available. Diffuse thickening of mitral valve leaflets with prolapse into the left atrial lumen. Severe eccentric mitral regurgitation with severe left atrial dilation. LV dilation with hyperdynamic myocardial function. The tricuspid valve appears mildly thickened with trace tricuspid regurgitation. Normal right heart. The pulmonic and aortic valves are normal in morphology and mobility. Normal pulmonic and aortic outflow velocities. No aortic or pulmonic insufficiency. No pericardial or pleural effusion noted. No obvious cardiac tumors observed.

CARDIAC CHART

CANINE CARDIAC PARAMETERS	MR VMAX (m/s)	TR VMAX (m/s)	LA/AO (Boon method)	LA/AO (Heart Base; Swe)	FS (%)	EF (%)	EPSS (cm)
NORMAL PARAMETER	4.5-5.5	<2.7	1.3	<1.6	28-40	40-100	<0.6
PATIENT	6.0	NM	2.3	2.2	52	84	NM
CANINE CARDIAC PARAMETERS	HR (BPM)	AV VMAX (m/s)	PV MAX (m/s)	BODY WEIGHT	LA 2D short axis Base view (cm)	LVIDd Avg; 2D and m-mode short axis (cm)	LVIDs Avg; 2D and m-mode short axis (cm)
NORMAL PARAMETER	50-100	0.7-1.7	0.7-1.6	BELOW	BELOW	BELOW	BELOW
PATIENT	160	1.0	1.3	12.4	2.4	3.5	1.7
*Normal chamber parameters expressed as a mean value (SD)				3	1.27 (5.3)	2.46 (2.46)	1.36 (5.5)
BODY WEIGHT DEPENDENT PARAMETERS				5	1.40 (4.5)	2.74 (5.2)	1.60 (4.7)
<i>*Note: All measurements based upon multi-modal images and methods. An average value is reported.</i>				10	1.50 (3.8)	3.27 (3.5)	2.06 (3.1)
				15	1.83 (2.0)	3.71 (2.4)	2.43 (2.1)
				20	2.02 (1.9)	4.14 (2.2)	2.80 (2.0)
				25	2.18 (2.4)	4.48 (2.9)	3.10 (2.5)
				30	2.33 (3.3)	4.83 (3.9)	3.39 (3.4)
				35	2.48 (4.3)	5.17 (5.0)	3.69 (4.5)
				40	2.62 (5.2)	5.48 (6.1)	3.96 (5.4)
				50	2.88 (7.1)	6.07 (8.3)	4.46 (7.4)

INTERPRETATION OF THE FINDINGS & FURTHER RECOMMENDATIONS

The murmur is due to chronic degenerative valve disease causing severe mitral and trace tricuspid regurgitation. Significant left atrial and ventricular enlargement indicate the risk for spontaneous congestive heart failure is elevated. No obvious additional issues are noted.

A cough in this patient with severe heart disease is likely multi-factorial in origin, including mainstem bronchi compression and/or potentially some degree of upper or lower airway disease. Early CHF/pulmonary edema should also be considered; however, this is less likely based upon the reported history. Recommend institute cardiac supportive medications including a weak



PATIENT

Layla Mendleson

diuretic (spironolactone), and advise close monitoring at home for need for Lasix therapy. Pending response, cough suppression (up to q4-6 hours) may also be helpful for mechanical cough. Monitoring of sleeping breathing rates is recommended as the best way to screen for CHF at home.

SPECIES

Canine

Omega fatty acid supplementation and mild salt restriction may also be of some long-term benefit. Monitor for development of a worsening cough, labored breathing, exercise intolerance or collapse episodes. Long term prognosis is guarded to poor, with an average survival time of 8-9mo for canine patients with active pulmonary edema on medications, however they generally are able to maintain a good quality of life for that period. Patient will always be at risk for recurrent CHF, development of arrhythmias/LA tear, syncope and/or sudden death in the future.

BREED

Pomeranian

SEX

Female Spayed

PLAN

Institute Pimobendan 0.3mg/kg PO q12h. Institute Spironolactone 1-2mg/kg PO q12h. Baseline BP recommended. If >130mmHg, institute ACE-I (benazepril or enalapril) 0.5mg/kg PO q12h. Consider hydrocodone with homatropine for QOL (0.2-0.4mg/kg PO up to q4-6 hours PRN for cough; available in 5/1.5mg tabs and 5mg/5ml liquid suspension).

AGE

10years

A renal panel is recommended in 1-2 weeks, then every 3-4 months lifelong.

WEIGHT

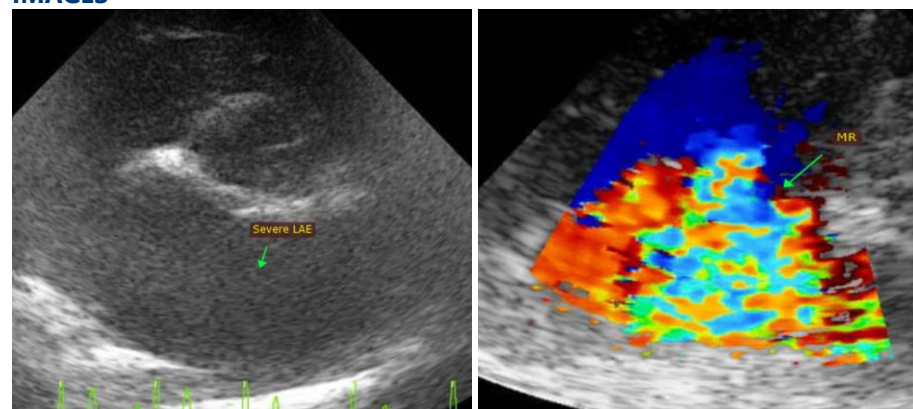
12.4

A recheck echocardiogram is recommended in 6 months to screen for progression, sooner if clinical signs arise.

INTERPRETED BY

Maggie Machen Lamy,
DVM, DACVIM
(Cardiology)

IMAGES



IMAGING PERFORMED BY

Sands Hill Mobile
Veterinary Ultrasound

HOSPITAL NAME

Whole Pet Vet

The information and recommendations provided are based on the images presented by the referring veterinarian. No evaluation can be communicated regarding pathology that was not visible in the image/video clips provided.

REFERRING VET

Dr. Calo

INVOICE

28598

Thank you for this referral. This report was generated using transcription software, and minor dictation errors may be present. If the clinical or image interpretation does not parallel your findings or if I can be of any further assistance, please contact me.

DATE

1/27/23/23

Maggie Machen Lamy, DVM
Diplomate of the American College of Veterinary Internal Medicine (Cardiology)



PATIENT

info@sonopath.com

Layla Mendleson

SPECIES

Canine

BREED

Pomeranian

SEX

Female Spayed

AGE

10years

WEIGHT

12.4

INTERPRETED BY

Maggie Machen Lamy,
DVM, DACVIM
(Cardiology)

**IMAGING
PERFORMED BY**

Sands Hill Mobile
Veterinary Ultrasound

HOSPITAL NAME

Whole Pet Vet

REFERRING VET

Dr. Calo

INVOICE

28598

DATE

1/27/23/23